

DEHORNING PROTOCOL



KRISHIMATE AGRO AND DAIRY PVT LTD

NO.1176, 1ST CROSS, 12TH B MAIN,

H A L 2ND STAGE, INDIRANAGAR

BANGALORE-560008, INDIA

Email: sales@srisaiagro.com

www.srisaiagro.com

Introduction

This affect is written to highlight the alternatives available to cow and dairy producers should they need to dehorn calves. As with all husbandry practices, painless alternatives such as breeding polled animals should be considered first.

Should dehorning be required it should be done as young as practicable. There are a number of methods available to dehorn young cattle.

Why dehorn cattle?

Bruising costs the Australian beef cattle industry an estimated \$20 million yearly. Extensive research in New South Wales and Queensland has shown that the single major cause of bruising is the presence of horns on cattle.

Dehorning is a short-term solution to the problem. In the long term, it is recommended that bruising and injury be reduced by breeding poll cattle.

Producers considering Cattle care accreditation are required to dehorn all calves.

Compared with hornless stock, horned cattle:

- Can cause more severe injury to other cattle, especially in yards, feedlots and transport;
- Can damage hides and cause bruising which reduces the value of carcasses;
- Are harder to handle in yards and crushes;
- Can be potentially more dangerous to handlers;
- Require more space at a feed trough and on cattle trucks;
- Are not as tractable and quiet to handle;
- May suffer discounts at sale especially if they are destined for feedlots.

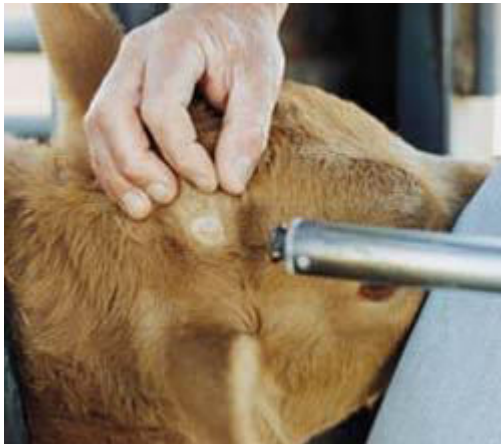Methods of dehorning

Calves up to two months old

On intensively managed properties, it is feasible to dehorn very young calves (up to two months old). Three methods are commonly used: hot iron, knife, and spoon or tube.

Hot iron

Various hot iron dehorning tools are available, including wood fire heated, LPG heated, butane gas heated and 12- and 24-volt electric models. Generally these methods are best suited to calves up to about 8 weeks of age.



Various hot iron dehorning tools are available, including wood fire heated, LPG heated, butane gas heated and 12- and 24-volt electric models. Generally these methods are best suited to calves up to about 8 weeks of age.

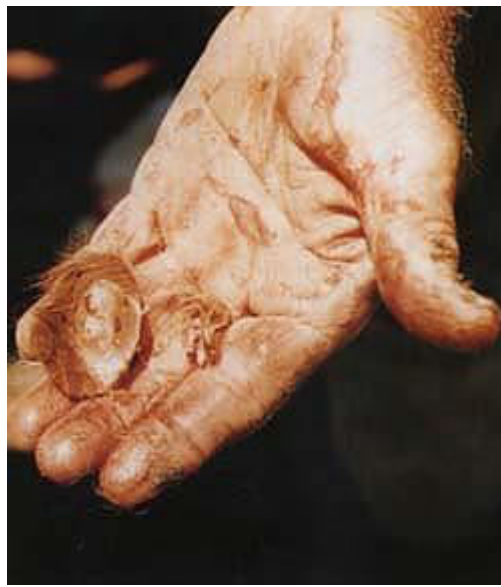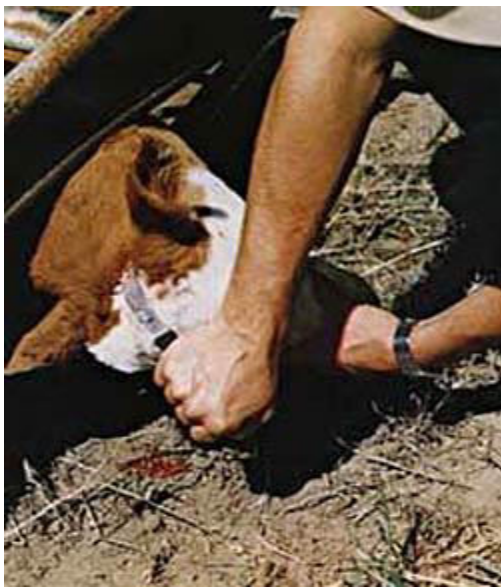With the calf firmly restrained and the iron heated to a cherry red Colour, apply the iron firmly over the emerging horn bud. Roll the hot iron over the horn bud several times so that a ring of tissue around the bud is burnt through the full thickness of

the skin. Heat must be transferred evenly all the way around the horn bud to ensure that the horn growth tissue is destroyed. In due course the horn bud will drop off.

The benefits of this method of dehorning are that it can be carried out at any time of the year. There is no loss of blood and no wound to become infected.

Knife

A curved knife similar to a farrier's knife (but without a hook on the end) can be used for dehorning. Start the cut about 2 cm away from the base of the horn, then draw the knife through the skin towards and through the horn, slicing off the horn level with the skull. This will remove an elliptical piece of skin with the horn in the Centre. If the cut has gone too near the edge of the horn so that the removed horn bud has an incomplete ring of hair, make another small cut to remove the skin to ensure no horn-forming tissue is left from which a scur (a rudimentary, deformed horn) may grow. Make the cut swiftly and firmly.



Spoon or tube dehorners

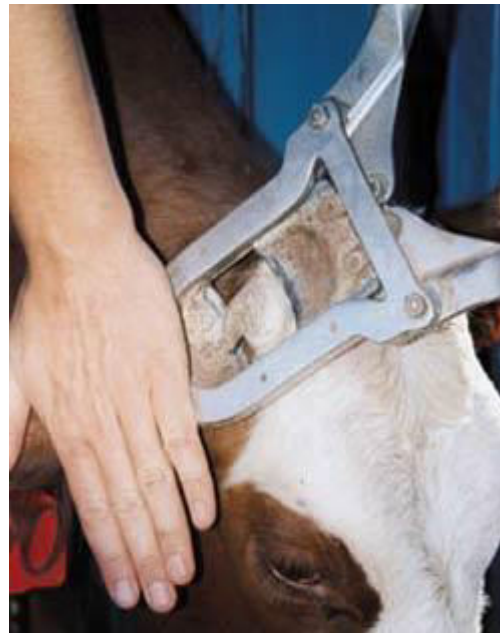These instruments are used in a similar way to the knife to remove the small horn bud

Older calves and weaners

The choice of tool for dehorning older calves (two to six months of age and weaners) is varied, but the most commonly used are the cup type (below left) or scoop type (below right) dehorners. Cup dehorners are operated with a scissor-like movement. The operator may need an assistant to apply downward pressure on the tool to stop it from riding up the horn and leaving some horn-forming tissue behind. The scoop type dehorner is pressed down vertically on the horn as the operator spreads the leverage arms.



Dehorning scoop



Dehorning cup

Both instruments are effective and easy to use. When removing the horn with either instrument the same principle applies as with the knife: at least a 1 cm ring of skin around the base of the horn must be removed.

Minimizing pain and stress

While dehorning has been an accepted part of cattle management for generations, greater awareness of animal welfare in recent years means that past methods can no longer be accepted without question. Dehorning by veterinarians using sedation and local anesthesia is accepted practice in Europe and should be encouraged in this country where practical, such as in small intensively managed situations. Impracticality of alternatives should not automatically be accepted as justification for the continued practice of painful procedures and producers need to take steps to minimize, whenever possible, the pain and stress that they inflict.

With the general community becoming increasingly concerned about animal welfare issues, dehorning is seen by many people as being cruel and offensive. The *Australian Model Code of Practice for the Welfare of Animals* (Cattle) describes what is considered to be best practice. The Code is quite specific in relation to dehorning.

If dehorning is to be carried out it should be done as young as possible to reduce stress and minimize animal welfare concerns.

There will be enormous long term benefits from having the Australian beef cattle herd horn-free and avoiding the high cost of bruising and hide damage.

Although dehorning of cattle may seem offensive to some people, it must be appreciated that the temporary discomfort caused by the operation is completely outweighed by the long-term benefits of having the whole herd free from damage caused by horns.

Legal requirements

The *Veterinary Surgeons Act 1986* defines dehorning as ‘the removal of the horn of an animal by methods which destroy or remove the keratin-producing cells and

structures at the base of the horn'. Horn-tipping is also defined by the Act, as 'the removal of the insensitive part of the horn of an animal'. State legislation makes dehorning of stock over the age of twelve months illegal without the use of anaesthetics. It may also be considered a cruelty offence under the *Prevention of Cruelty to Animals Act*.

When to dehorn

Calves should be dehorned as early as possible. A tight calving pattern allows all calves to be dehorned at a similar age, effectively and humanely. If the calving pattern is spread out, select groups of calves of similar ages for dehorning

It is best to dehorn calves at less than three months of age. They suffer less stress because they are more easily handled, and the preferred methods cause little or no bleeding, heal quickly, and do not result in any significant setbacks.

Cattle should be dehorned on dry cool days to allow the wound to dry quickly with the minimum risk of infection. The best time is late afternoon, when fly activity is usually low. Never dehorn cattle in wet weather, because the healing rate is decreased and the risk of infection increased.

Facilities and restraint

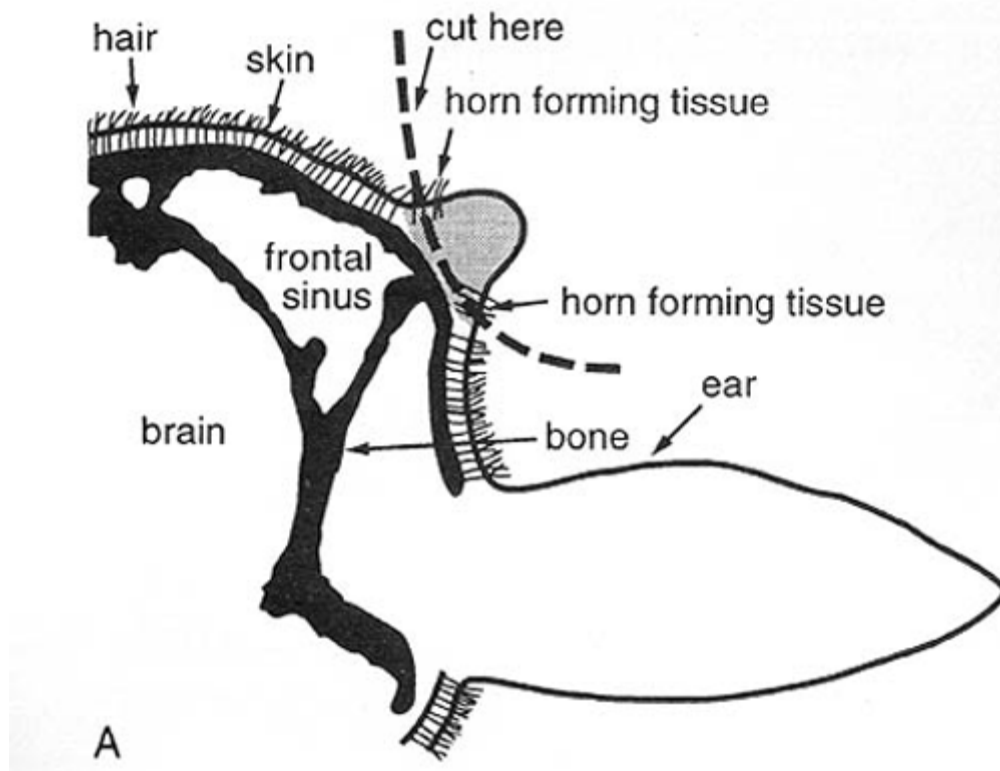
A well designed calf cradle will restrain the calf and ensure that dehorning can be done effectively while minimizing stress and effort for both the operator and the calf. When a calf is restrained in a cradle, all marking and vaccination procedures can be done easily. Dehorning should be done last at marking time after calves are vaccinated and castrated.

Hygiene and care of equipment

Before dehorning, sharpen the blades of all dehorning instruments on an oilstone, then disinfect them in a bucket of antiseptic solution. Disinfect dehorners also between calves. This will allow dehorning to be completed smoothly and cleanly, reducing stress on both the operator and the animal. Blades will need to be re-sharpened if they become dull.

Anatomy - where to cut and apply dehorners

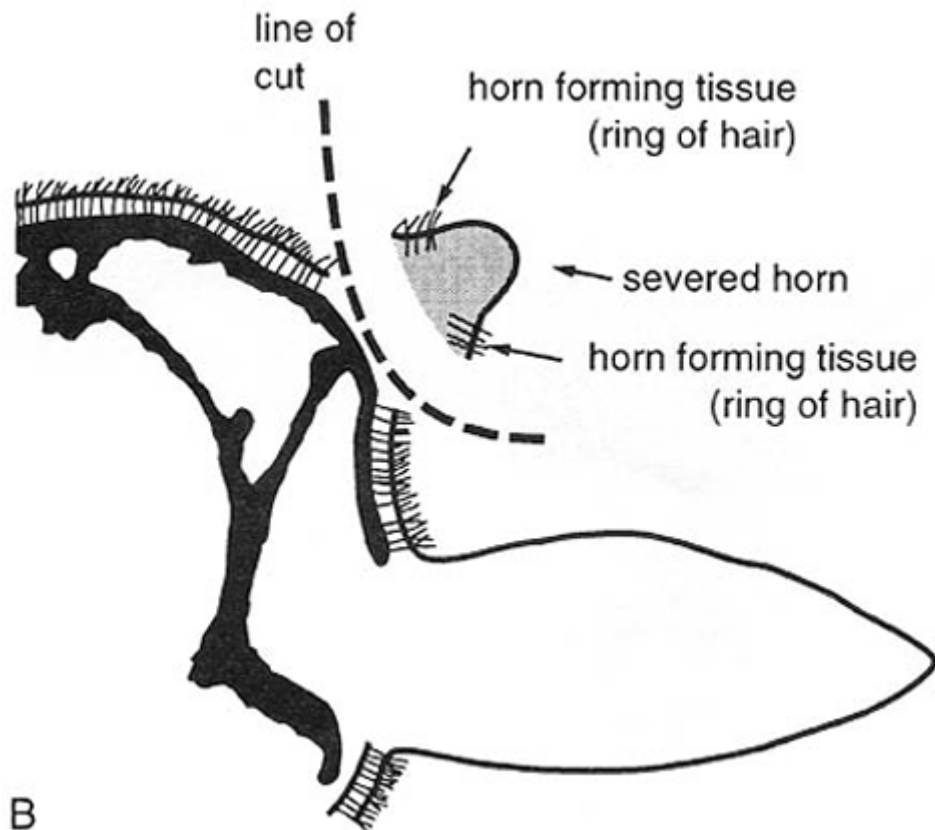
For dehorning to be done successfully, operators need a basic knowledge of the internal structure of the horn and how it develops.



As shown in diagram A above, the horn grows from the skin around its base in much the same way as the wall of the hoof grows down from the skin of the

coronet of the foot. In young calves up to about two months of age, the horn bud is free-floating in the skin layer above the skull. As the calf grows older, the horn bud attaches to the skull and a small horn starts to grow.

Dehorning should be performed before this attachment to the skull occurs. It then becomes a much simpler exercise, and results in far less bleeding.



To ensure that there will be no regrowth of the horn after dehorning, the operator must remove the horn-forming tissue. This is done by removing a ring of skin at least 1 cm wide with the horn bud (see diagram B above).

The most common mistake when dehorning is to remove an incomplete ring of hair around the horn bud. This allows a scur to grow. Take care to dehorn all calves and to dehorn them carefully and accurately, remembering the '1 cm rule'. If the horn

bud has an incomplete ring of hair, a second cut will be needed to remove all horn-forming tissue.

Once the horn bud attaches to the skull, the horn core becomes a bony extension of the skull and the hollow Centre of the core opens directly into the frontal sinuses of the skull. In this situation, the frontal sinuses are opened and the soft membranous covering of the cranium (skull) is often exposed to view. This is not the brain (as is sometimes thought) and its exposure does not harm the calf. In older calves it takes only a short time after dehorning for this opening to close, but it is during this period that the animal is prone to fly strike and sinus infections.

Treatment after dehorning

After the operation, animals may bleed freely for a short time. Heat cauterising of the wound of older calves is gaining acceptance as a means of reducing blood loss and drying out the wound.

The application of a proprietary wound dressing powder (dusting powder) is often sufficient treatment; a powder that contains a fly repellent is recommended if dehorning in the warmer months when flies are a problem.

Dehorning pads are available from many rural merchants. These are placed on the wound and reduce the amount of blood loss from the operation. The pads are left on the wound until they drop off with the scab.

As stated on the Code of Practice, after dehorning, cattle should be inspected regularly for the first 10 days and any infected wounds treated.

Horn tipping



The removal of the sharp points of the horns of adult cattle is known as horn tipping. This procedure is of little value in reducing the amount or severity of bruising on carcasses, but tipping can relieve the irritation caused when a curled horn grows back into the head. The operation can sometimes be done by placing large dehorners over the horn tip. Where this is not possible, embryology wire is used to saw through the horn tip.

Acknowledgement

Rod Thompson, former Livestock Officer (Beef Cattle) with the Department of Agriculture's Research and Advisory Station at Glen Innes, prepared much of the original material on which this publication is based.